

A RETROSPECTIVE STUDY ON 83 ONE-PIECE IMPLANTS INSTALLED IN RESORBED MAXILLAE

S. FANALI¹, F. CARINCI², I. ZOLLINO²,
C. BRUGNATI³, D. LAURITANO⁴

¹Department of Oral Science, Nano and Biotechnology, University "G. D'Annunzio", Chieti, Italy

²Department of D.M.C.C.C., Section of Maxillofacial and Plastic Surgery, University of Ferrara, Ferrara, Italy

³Department of Dentistry and Maxillofacial Surgery, Don Orione Institute, Bergamo, Italy

⁴Department of Neurosciences and Biomedical Technologies, University Milano Bicocca, Italy

One-piece implants incorporate the trans-mucosal abutment facing the soft tissues as an integral part of the implant. The interface between the trans-mucosal component and the implant is generally located in the neighborhood of the alveolar bone level. One-piece implants are usually welded together and immediately loaded. Since no report on one-piece implants placed in maxilla is available, a retrospective study was performed. Twelve patients (5 females and 7 males) were enrolled in the present study. A total of 83 one-piece implants (Diamond, BIOIMPLANT, Milan, Italy) were inserted. Cox analysis was used to detect if any of the studied variables (i.e. diameter, length, replaced tooth position and welding) has an impact both on failures (SVR, i.e. lost fixtures) and/or on success (SCR, i.e. crestal bone resorption around implants lower than 1.5 mm). In our series SVR and SCR were 86.7 (i.e. 11 implants lost) and 97.2 (i.e. 2 failures out of the remaining 72 implants), respectively. Statistical analysis demonstrated that replaced tooth position has a direct impact on survival (i.e. lost implants) with a worse survival for premolars and molars (80.1 % survival) respect to incisors and canine (92.7% survival) ($p=0.03$). No studied variables (i.e. diameter, length, replaced tooth position and welding) have impact on clinical success (i.e. crestal bone resorption). Since maxilla has a lower bone quality respect to mandible, we concluded that one-piece implants are reliable devices for maxilla rehabilitation.

For several years, to submerge and to unload implants during the healing period were major guidelines of osteointegration (1). It was believed that micromovement of implants –due to functional force around the bone-implant interface during wound healing- induces fibrous tissue formation rather than bone contact, leading to clinical failure (1). In addition, coverage of an implant has also been thought to prevent infection and epithelial down-growth (2, 3). Consequently, standard protocols require to submerge and to unload implants during the healing period in order to avoid peri-implant infections and to gain in bone formation. Usually, the second surgical procedure is performed after three and six months in mandible and maxillae, respectively (4, 5).

Recently, several authors have focus on implants' immediate functional loading in order to minimize the

delay between surgical and prosthetic phases (6, 7). Immediate loading means to place the (final or provisional) prosthetic restoration on implant immediately or within 48 hours from the surgical procedure (7). Two types of immediate loading exists: (1) the immediate functional loading (IFL) if the prosthetic crown is in occlusion, and (2) the immediate non functional loading (INFL) if the prosthetic crown is not in occlusion (7). Several reports have shown that immediate loading can lead clinical and histological osteointegration (7, 8).

Salama et al (9) reported two cases in which immediate loading of titanium root-form implants was successfully utilized to support provisional fixed restorations in the maxilla and the mandible. Surprising, all immediate loading implants were still in place after 3-years follow-up.

Key words: One-piece, implant, fixture, welding, bone, immediate loading.

Corresponding author: Prof. Francesco Carinci, M.D
Department of D.M.C.C.C Section
of Maxillofacial and Plastic Surgery
University of Ferrara
Corso Giovecca 203, 44100 Ferrara ITALY
E-mail: crc@unife.it Web: www.carinci.org
Phone: +39.0532.455874 Fax: +39.0532.455876

55 (S2)

0393-974X (2012)

Copyright © by BIOLIFE, s.a.s.

This publication and/or article is for individual use only and may not be further reproduced without written permission from the copyright holder. Unauthorized reproduction may result in financial and other penalties

Tarnow and coworkers (10) reported the effects of IFL in six completely edentulous mandible and four maxillae. Sixty-seven out of 69 immediate loaded implants had successful outcome.

Grunder (11) reported the effect of IFL in 91 fixtures placed both in mandible and maxillae, 66 of them were placed immediately after tooth extraction. The author reported an overall success rate of 92.31%, ranged from 87.5 to 97.26 for maxillae and mandible after 2 years follow-up.

Olsson et al. (12) treated ten patients with totally edentulous jaws. Implants were loaded after 1 to 9 days. Only 4 implants were lost in a follow-up period of 1 year.

Since one-piece implants became more and more popular (13-16) and no report focusing on implants inserted in the maxillae is available we therefore decided to perform a retrospective study.

MATERIALS AND METHODS

A) Study design/sample

To address the research purpose, the investigators designed a retrospective cohort study. The study population was composed of patients at the Dental Clinic, University of Chieti, Italy for evaluation and implant treatment by S.F. between January and December 2010. The study design was similar to those of previously reported study (13-16).

Subjects were screened according to the following inclusion criteria: controlled oral hygiene and absence of any lesions in the oral cavity; in addition, the patients had to agree to participate in a post-operative check-up program.

The exclusion criteria were as follows: bruxists, smoking more than 20 cigarettes/day, consumption of alcohol higher than 2 glasses of wine per day, localized radiation therapy of the oral cavity, antitumor chemotherapy, liver, blood and kidney diseases, immunosuppressed patients, patients taking corticosteroids, pregnant women, inflammatory and autoimmune diseases of the oral cavity.

B) Variables

Several variables are investigated: demographic (age and gender), anatomic (tooth site), implant (length and diameter), and prosthetic (welding procedure) variables.

Primary and secondary predictors of clinical outcome are used. The primary predictor is the presence/absence of the implant at the end of the observation period. It is defined as survival rate (i.e. SVR) that is the total number of implants still in place at the end of the follow-up period.

The second predictor of outcome is the peri-implant bone resorption. It is defined as implant success rate (SCR) and it is evaluated according to the absence of persisting peri-implant bone resorption greater than 1.5 mm during the first year of loading and 0.2 mm/years during the following years (17).

C) Data collection methods

Before surgery, radiographic examinations were done with the use of orthopantomographs and CT scans.

Peri-implant crestal bone levels were evaluated by the calibrated examination of orthopantomograph x-rays after surgery and at the end of the follow-up period. The measurements were carried out medially and distally to each implant, calculating the distance between the implant neck and the most coronal point of contact between the bone and the implant. The bone level recorded just after the surgical insertion of the implant was the reference point for the following measurements. The measurement was rounded off to the nearest 0.1 mm. The radiographs were performed with a computer system (Gendex, KaVo ITALIA srl,

Genova, Italia) and saved in uncompressed TIFF format for classification. Each file was processed with the Windows XP Professional operating system using Photoshop 7.0 (Adobe, San Jose, CA), and shown on a 17" SXGA TFT LCD display with a NVIDIA GE Force FX GO 5600, 64 MB video card (Acer Aspire 1703 SM-2.6). By knowing dimensions of the implant, it was possible to establish the distance from the medial and distal edges of the implant platform to the point of bone-implant contact (expressed in tenths of a millimeter) by doing a proportion.

The difference between the implant-abutment junction and the bone crestal level was defined as the Implant Abutment Junction (IAJ) and calculated at the time of operation and at the end of the follow-up. The delta IAJ is the difference between the IAJ at the last check-up and the IAJ recorded just after the operation. Delta IAJ medians were stratified according to the variables of interest.

D) Surgical protocol

All patients underwent the same surgical protocol. An antimicrobial prophylaxis was administered with 1g Amoxicillin twice daily for 5 days starting 1 hour before surgery. Local anesthesia was induced by infiltration with articaine/epinephrine and post-surgical analgesic treatment was performed with 100 mg Nimesulid twice daily for 3 days. Oral hygiene instructions were provided.

One-piece implants (Diamond, BIOIMPLANT, Milan, Italy) (Fig. 1) were inserted with a trans-mucosal approach. The implant neck was positioned at the alveolar crest level. Welding procedure was performed by using an intra-oral welding machine Dent Weld (Swiss & Wegman S.r.l., Ponte San Nicolò (PD) Italy). A provisional prosthesis was immediately provided and the final restoration was usually delivered within 8 weeks. All patients were included in a strict hygiene recall.

E) Data analysis

Cox analysis was used to detect if diameter, length, welding and replaced tooth position have an impact both on failures (i.e. lost fixtures) and/or on success (i.e. crestal bone resorption around implants lower than 1.5 mm).

RESULTS

Twelve patients (5 females and 7 males) have the inclusion criteria and were enrolled in the present study. The mean implant follow-up was 8 months.

A total of 83 one-piece implants (Diamond, BIOIMPLANT, Milan, Italy) were inserted in the maxilla. Implants were inserted to replace 26 incisors, 15 cuspids, 26 premolars and 16 molars. Implant length was shorter than 13 mm, equal to 13 mm and longer than 13 mm in 21, 19 and 43 fixtures, respectively. Implant diameter was narrower than 4 mm, equal to 4 mm and wider than 4 mm in 6, 51 and 26 fixtures, respectively. Seventy-four implants were welded. Thirty-five were placed in females and 48 in males.

Eleven implants were lost in the post-operative period, SVR = 86.7%. Cox analysis demonstrated that replaced tooth position has a direct impact on survival (i.e. lost implants) with a worse survival for premolars and molars (80.1 % survival) respect to incisors and canine (92.7% survival) (p=0.03).

Then peri-implant bone resorption (i.e. delta IAJ) was used to investigate. Out of the 72 remaining implants, two fixtures have a crestal bone resorption greater than 1.5 mm (SCR = 97.2) and thus were used for statistical

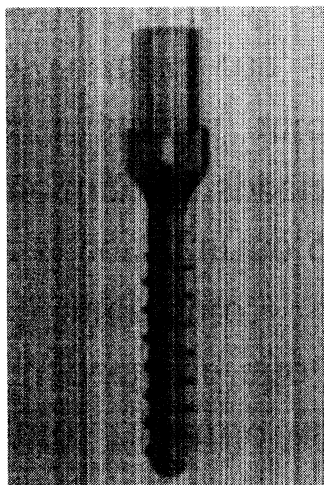


Fig. 1. Narrow diameter one-piece implant

purpose. Cox analysis demonstrated that no studied variables (i.e. diameter, length, replaced tooth position and welding) have impact on clinical success (i.e. crestal bone resorption).

DISCUSSION

High success rates for immediately loaded implants were first documented in the middle '80s, when the one-stage implants protocol gained popularity. Babbush et al. (18) reported a cumulative success rate of 88% on 1739 immediately loaded TPS implants. Subsequently, many authors have shown the possibility of loading implants immediately after implant surgery with a success rate similar to the traditional two-stage approach (9, 19) (7, 8, 20).

Maxilla has a lower bone quality than mandible and bone quality is believed to be the strongest predictor of outcome in immediate loading. Immediate loading of the totally edentulous maxilla has been presented in the literature with promising outcomes (11, 12). Here we reported a SVR=86.7% which is compatible with implants inserted in upper jaw. In addition worse results were detected for distal teeth respect to incisors and cuspid since in that area there is lower bone quantity and quality.

Number of fixtures is an additional variable that has to be considered during planning. Previously, some Authors have suggested to use 10 or more implants for IFL (11, 12). Discrepancy may lay on surgical technique a balanced distribution of implants (and force) over the long alveolar arch. Is of paramount importance in edentulous maxillae. A crowded distribution of fixtures can increase the risk of failure because of insufficient quantity of bone per fixture,

high drilling stress on bone per square cm and higher probability of transmitted infection among implants. Moreover, most edentulous maxillae have sufficient bone for 6 implants in the premolar to premolar region, but seldom can carry 8 or more implants. Furthermore, the use of many implants increases dramatically the cost of treatment. No specific data is still available for one-piece implants.

One-piece fixtures became more and more popular in the last few years. They incorporate the trans-mucosal abutment facing the soft tissues as an integral part of the implant. The interface between the trans-mucosal component and the implant is generally located in the neighborhood of the alveolar bone level. In a one-piece implant the fixture immediately pierces the soft tissue's barrier (non-submerged fashion) according to a one-stage surgery, whereas a two-piece implant system is submerged under the soft tissues for a waiting period (two-stage surgery) (21).

Thus, with a one-piece implant design, manipulation of the peri-implant soft tissue after initial healing can be avoided. The implant can be provided with a provisional restoration at placement, allowing for the mucosal epithelium and the connective tissue adhesion to form coronal to the alveolar crest (22). The preparable abutment portion of the implant makes it possible to create an individualized profile that follows the contour of the gingival margin without violating the soft tissue seal (21).

The surgical protocol for placement of this implant includes both flap and flapless procedures (23). However, avoiding separation of the periosteum from the underlying tissue may result in a better-maintained blood supply to the marginal bone, thus reducing the likelihood of bone resorption. So, decreased postoperative bleeding, less discomfort for the patient, shorter surgery time and reduced healing time are reported advantages for the flapless procedure compared to that involving a flap (24, 25).

In conclusion we demonstrated that one-piece implants are reliable devices for maxilla rehabilitation.

REFERENCES

1. Adell R, Lekholm U, Rockler B, Branemark PI. A 15-year study of osseointegrated implants in the treatment of the edentulous jaw. *Int J Oral Surg* 1981; 10:387-416.
2. Branemark PI, Hansson BO, Adell R, Breine U, Lindstrom J, Hallen O, Ohman A. Osseointegrated implants in the treatment of the edentulous jaw. Experience from a 10-year period. *Scand J Plast Reconstr Surg Suppl* 1977; 16: 1-132.

3. Branemark PI, Zarb G, Albrektsson T. Tissue-integrated prosthesis: osseointegration in clinical dentistry. Chicago: Quintessence; 1985.
4. Branemark PI. Osseointegration and its experimental background. *J Prosthet Dent* 1983; 50:399-410.
5. Hansson HA, Albrektsson T, Branemark PI. Structural aspects of the interface between tissue and titanium implants. *J Prosthet Dent* 1983; 50:108-13.
6. Cooper L, Felton DA, Kugelberg CF, Ellner S, Chaffee N, Molina AL, Moriarty JD, Paquette D, Palmqvist U. A multicenter 12-month evaluation of single-tooth implants restored 3 weeks after 1-stage surgery. *Int J Oral Maxillofac Implants* 2001; 16:182-92.
7. Degidi M, Piattelli A. Immediate functional and non-functional loading of dental implants: a 2- to 60-month follow-up study of 646 titanium implants. *J Periodontol* 2003; 74:225-41.
8. Degidi M, Piattelli A. Immediately loaded bar-connected implants with an anodized surface inserted in the anterior mandible in a patient treated with diphosphonates for osteoporosis: a case report with a 12-month follow-up. *Clin Implant Dent Relat Res* 2003; 5:269-72.
9. Salama H, Rose LF, Salama M, Betts NJ. Immediate loading of bilaterally splinted titanium root-form implants in fixed prosthodontics—a technique reexamined: two case reports. *Int J Periodontics Restorative Dent* 1995; 15:344-61.
10. Iarnow DR, Emtiaz S, Classi A. Immediate loading of threaded implants at stage I surgery in edentulous arches: ten consecutive case reports with 1- to 5-year data. *Int J Oral Maxillofac Implants* 1997; 12:319-24.
11. Grunder U. Immediate functional loading of immediate implants in edentulous arches: two-year results. *Int J Periodontics Restorative Dent* 2001; 21:545-51.
12. Olsson M, Urde G, Andersen JB, Sennerby L. Early loading of maxillary fixed cross-arch dental prostheses supported by six or eight oxidized titanium implants: results after 1 year of loading, case series. *Clin Implant Dent Relat Res* 2003; 5 Suppl 1:81-7.
13. Fanali S, Carinci F, Zollino I, Brunelli G, Monguzzi R. Effect of distance between one piece implants on crestal bone resorption. *European Journal of Inflammation* 2011; 3 (S):1-6.
14. Fanali S, Carinci F, Zollino I, Brunelli G, Monguzzi R. Effect of one-piece implant diameter on clinical out come. *European Journal of Inflammation* 2011; 3 (S):7-12.
15. Fanali S, Carinci F, Zollino I, Brunelli G, Monguzzi R. Effect of one-piece implant lenght on clinical out come. *European Journal of Inflammation* 2011; 3 (S):13-18.
16. Fanali S, Carinci F, Zollino I, Brunelli G, Monguzzi R. Welding improbe the success rate of one-piece implants. *European Journal of Inflammation* 2011; 3 (S):19-24.
17. Albrektsson T, Zarb GA. Determinants of correct clinical reporting. *Int J Prosthodont* 1998; 11:517-21.
18. Babbush CA, Shimura M. Five-year statistical and clinical observations with the IMZ two-stage osteointegrated implant system. *Int J Oral Maxillofac Implants* 1993; 8: 245-53.
19. Piattelli A, Ruggeri A, Franchi M, Romasco N, Trisi P. An histologic and histomorphometric study of bone reactions to unloaded and loaded non-submerged single implants in monkeys: a pilot study. *J Oral Implantol* 1993; 19:314-20.
20. Ganeles J, Rosenberg MM, Holt RL, Reichman LH. Immediate loading of implants with fixed restorations in the completely edentulous mandible: report of 27 patients from a private practice. *Int J Oral Maxillofac Implants* 2001; 16:418-26.
21. Rompen E, Domken O, Degidi M, Pontes AE, Piattelli A. The effect of material characteristics, of surface topography and of implant components and connections on soft tissue integration: a literature review. *Clin Oral Implants Res* 2006; 17 Suppl 2:55-67.
22. Drago CJ. Clinical and histological assessment of a one-piece implant system: a pilot study. *Dental Praxis* 2005; 11/12:319-25.
23. Finne K, Rompen E, Toljanic J. Prospective multicenter study of marginal bone level and soft tissue health of a one-piece implant after two years. *J Prosthet Dent* 2007; 97:S79-85.
24. Fortin T, Bosson JL, Isidori M, Blanchet E. Effect of flapless surgery on pain experienced in implant placement using an image-guided system. *Int J Oral Maxillofac Implants* 2006; 21:298-304.
25. Rocci A, Martignoni M, Gottlow J. Immediate loading in the maxilla using flapless surgery, implants placed in predetermined positions, and prefabricated provisional restorations: a retrospective 3-year clinical study. *Clin Implant Dent Relat Res* 2003; 5 Suppl 1:29-36.